



PRESENTING CLINICAL SIGNS

History: Grade 3/6 murmur. Elevated BNP.

DATE

2/14/23

ECHOCARDIOGRAPHIC FINDINGS

2D, M-mode, and Doppler study.

PERFORMED BY

Kelly Vazquez

Left atrial size is normal. The mitral valve appears normal, though mild mitral regurgitation is present. Left ventricular wall thickness is normal. Left ventricular internal dimensions are normal. Left ventricular systolic function is mildly hyperdynamic. The aorta and aortic are normal. Right atrial and right ventricular dimensions are normal. The tricuspid valve is normal. The pulmonary artery and pulmonic valve are normal. No pericardial effusion or cardiac masses are seen.

INTERPRETED BY

Keith Blass, DVM,
MS, DACVIM
(Cardiology)

LA/Ao - 1.46
IVSd - 5.7 mm
LVPWd - 5.6 mm
LVIDd - 15.4 mm
LVIDs - 7.3 mm
FS - 52.6%
LVOT - 1.39 m/s
RVOT - 0.94 m/s

PATIENT

Marley Smoak

ASSESSMENT/RECOMMENDATIONS

SPECIES

Feline

This examination demonstrates mild regurgitation of blood across Marley's mitral valve. The hemodynamic effects of the regurgitation also appear to be mild, as Marley does not have secondary dilation of either of his left heart chambers. Given the absence of left atrial dilation, Marley's current risk for the development of congestive heart failure and/or thromboembolic disease appears to be low, though careful monitoring for progression is recommended.

BREED

No therapy is recommended based on this exam.

DSH

A recheck echocardiogram is recommended in 6-9 months. Thoracic radiographs are recommended if Marley experiences respiratory clinical signs.

SEX

MN

AGE

13 y

WEIGHT

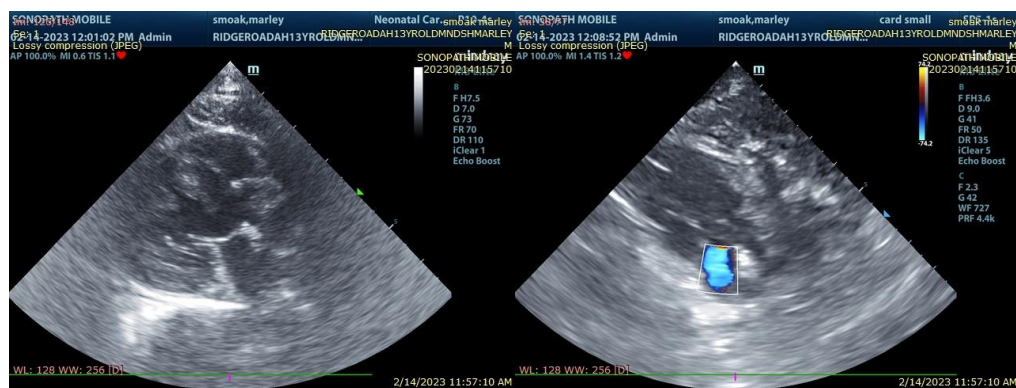
21.4 lb

HOSPITAL NAME

Ridge Road AH

REFERRING VET

Dr. Pathak



The information and recommendations provided are based on the images presented by the referring veterinarian. No evaluation can be communicated regarding pathology that was not visible in the image/video clips provided.

Thank you for this referral. If the clinical or image interpretation does not parallel your findings or if I can be of any further assistance please contact me.



Keith Blass, DVM, MS, DACVIM (Cardiology)

KeithBlass@gmail.com

631-804-5754

DATE

2/14/23

PERFORMED BY

Kelly Vazquez

INTERPRETED BY

Keith Blass, DVM,
MS, DACVIM
(Cardiology)

PATIENT

Marley Smoak

SPECIES

Feline

BREED

DSH

SEX

MN

AGE

13 y

WEIGHT

21.4 lb

HOSPITAL NAME

Ridge Road AH

REFERRING VET

Dr. Pathak